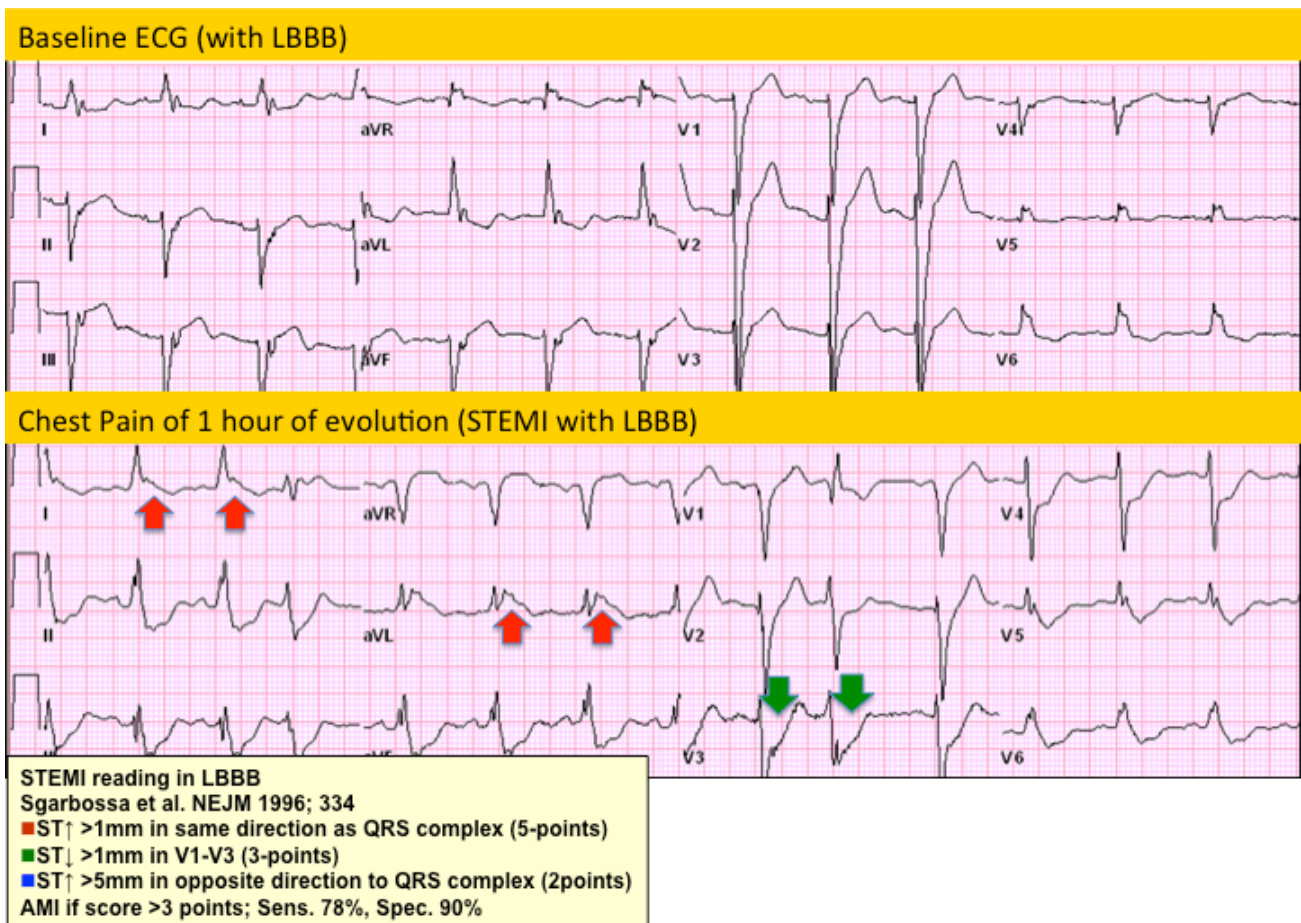


Case 14: Questions & Answers:

1. STEMI? Yes. Chronic LBBB.
2. Territory? Lateral.
3. What is the Culprit Vessel? Circumflex.

The superior ECG is the patient's baseline ECG with evidence of a chronic LBBB. The lower ECG is related to his ER evaluation with CP of one-hour evolution. This ECG presents two Sgarbossa's criteria for AMI with LBBB, including: STE of > 1 mm in the same direction of the QRS vector & ST depression > 1 mm in any lead from V1- V3.



By: Jose Escabi-Mendoza, MD FACC