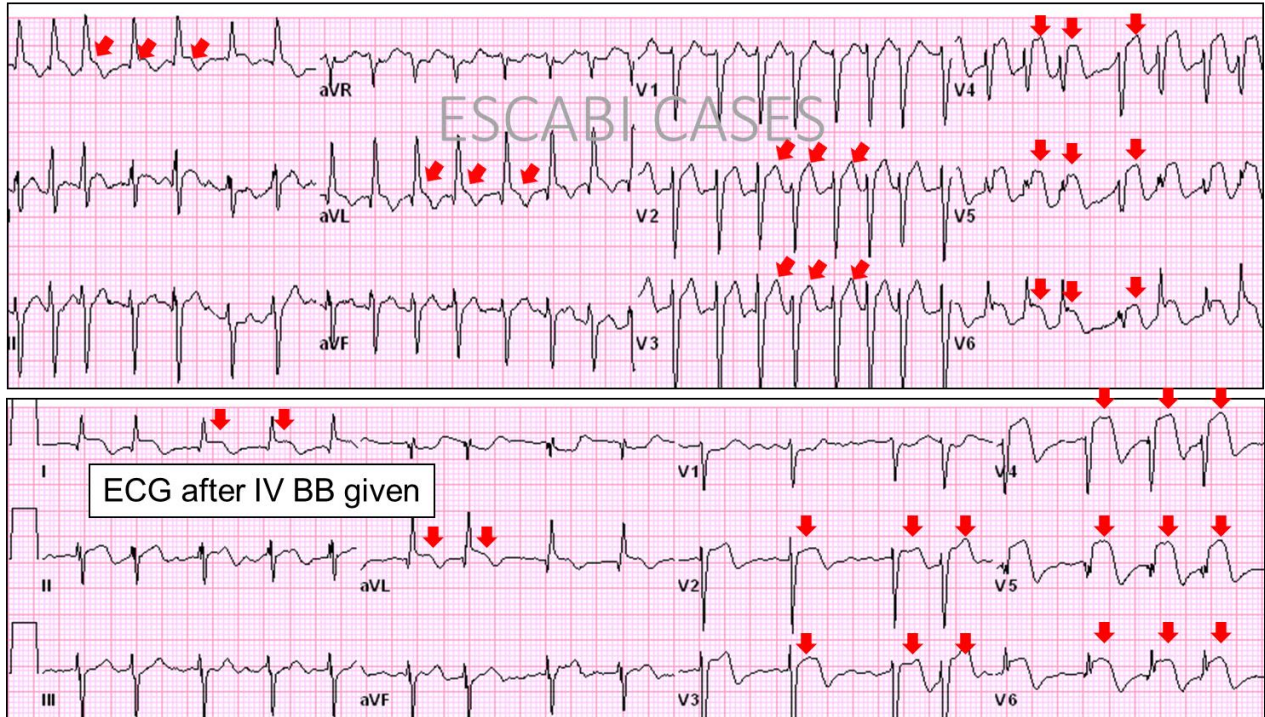


Case 7: Questions & Answers:

- 1. STEMI? Yes
- 2. Territory? Anterior and lateral walls.
- 3. What is the Culprit Vessel? Non-proximal LAD

His presenting ECG revealed a new atrial fibrillation with a fast ventricular rate in 180 beats/min. After administration of metoprolol IV his HR decreased to 102/min with clear anterolateral STE consistent w injury.



By: Jose Escabi-Mendoza, MD, FACC