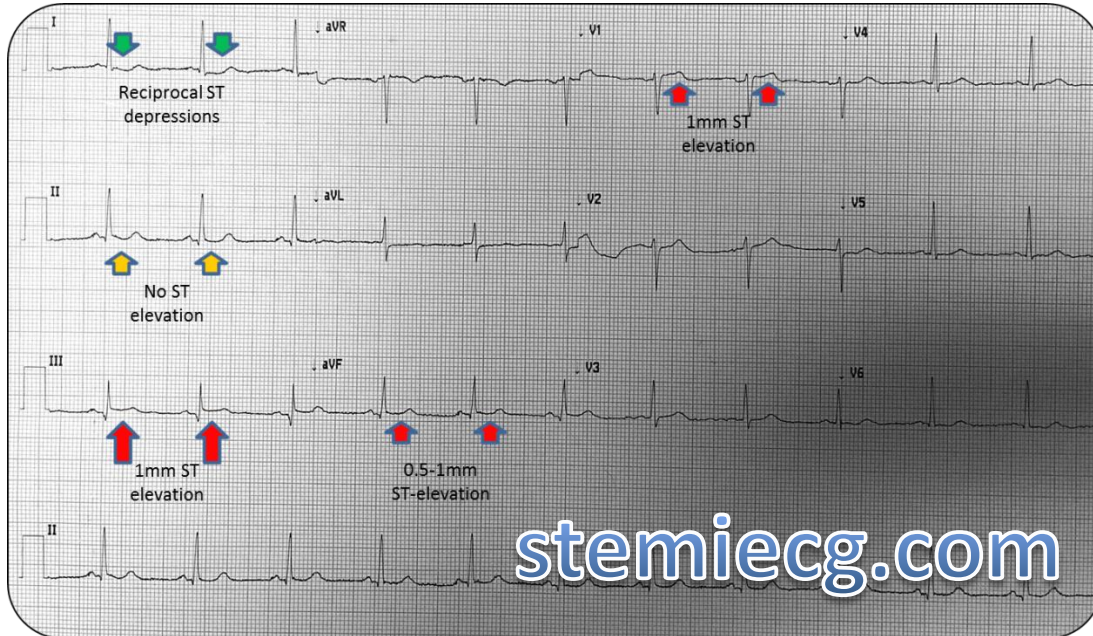


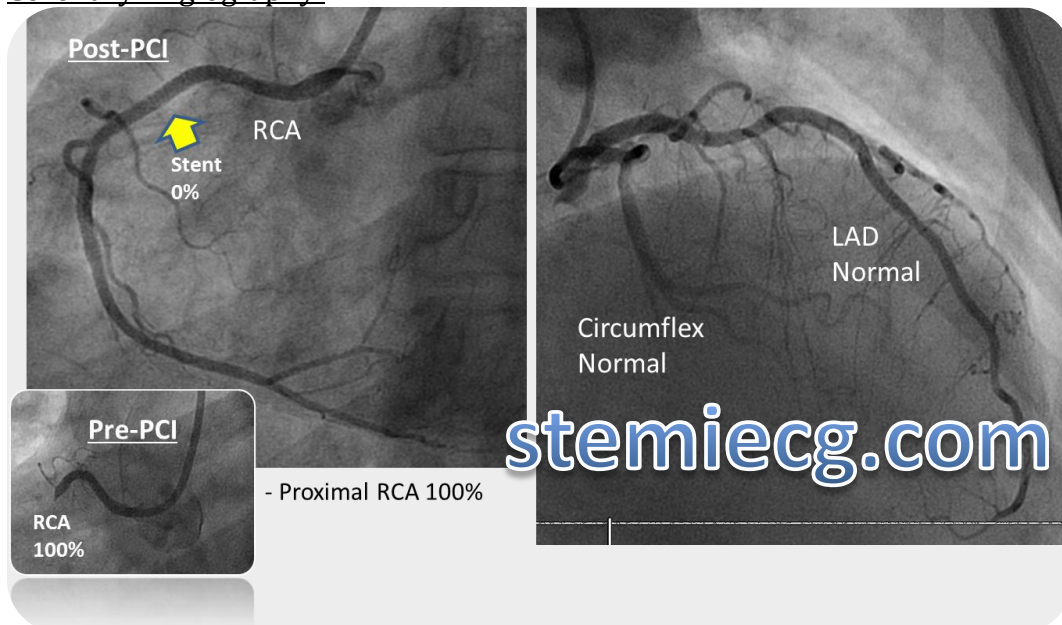
Case #16: Questions & Answers:

1. STEMI? Yes.
2. Territory? Inferior with RV
3. What is the Culprit Vessel? Proximal RCA.

Right Ventricle STEMI findings in this case: Early and subtle inferior ST segment elevations (STE LIII > LII), with precordial V-1 STE and associated L-1 reciprocal ST depression.

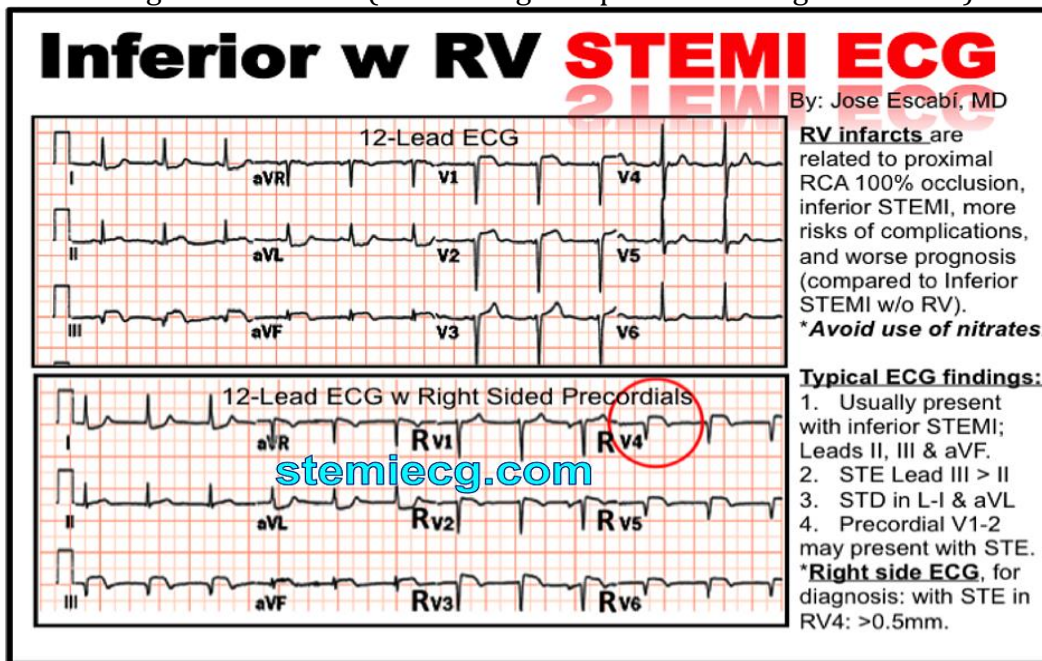


Coronary Angiography:



Discussion points:

1. ECG Findings of RV STEMI: (Do not forget to perform the right side ECG)



2. Recognize the importance of reciprocal changes associated to subtle STEMI

Reciprocal ST Segment Depression Related to STEMI

stemiecg.com

- Defined as ST segment depression distant (opposite wall) from STEMI.
- Seen in 75% of inferior AMI & 30% anterior AMI (also seen with other STE walls).
- Increases diagnostic accuracy of STEMI when present (PPV of > 90%)
- Most useful w subtle STE
- Associated with:
 - Larger AMI
 - Lower resultant EF
 - Increased mortality

Brady et al. Am J Emerg Med 2007; 20: 35

By: Jose Escabi-Mendoza, MD

www.stemiecg.com