Case #39: Questions & Answers:

1. Acute STEMI? Probably yes, but not certain in view of active COVID-19 infection.
2. Territory? High lateral and likely posterior STEMI or acute wall injury.
3. Management?

a) **Emergent Primary PCI**
b) **Fibrinolytics**
c) ***Medical management without reperfusion treatment***

Arrival ECG Findings:

- **The patient's arrival 12-lead ECG (figure-1) did not present any acute ischemic ST-segment changes.**
- **His f/u ECG (figure-2) performed 5wks after in view of persistent hypotension despite vasopressor therapy and with active ARDS, hypoxemia despite FiO2 of 100% and active DNR status.**
- **ECG findings (figure-2) with high lateral ST segment elevations (aVL and L-1) as marked with red arrows, with ST segment depressions upon V3-V6 (>2mm) suggestive of concomitant posterior STE (blue arrows).**
- **Inferior leads (LII, LIII and aVF) with ST segment depressions (reciprocal depressions: green arrows) as may occur with high lateral STEMI cases.**

Figure-1: Arrival ECG (baseline)

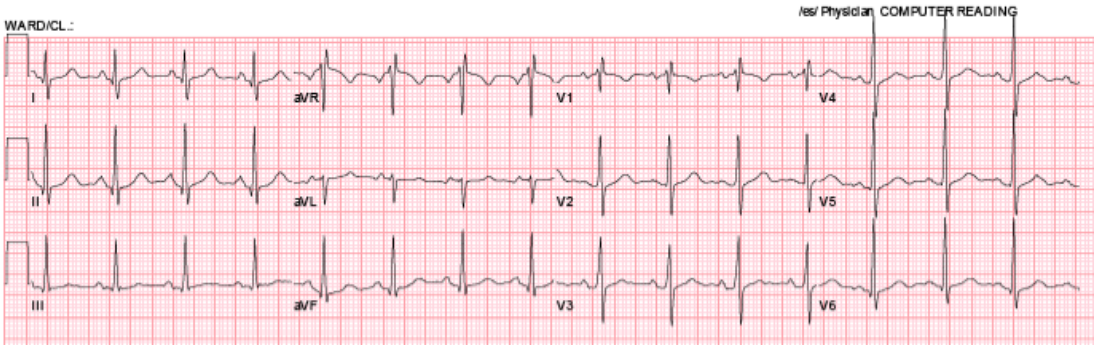

Figure-2: Follow-up ECG (5wks after) upon mark hypotension on a persistent COVID-19 positive patient with ARDS and septic shock:

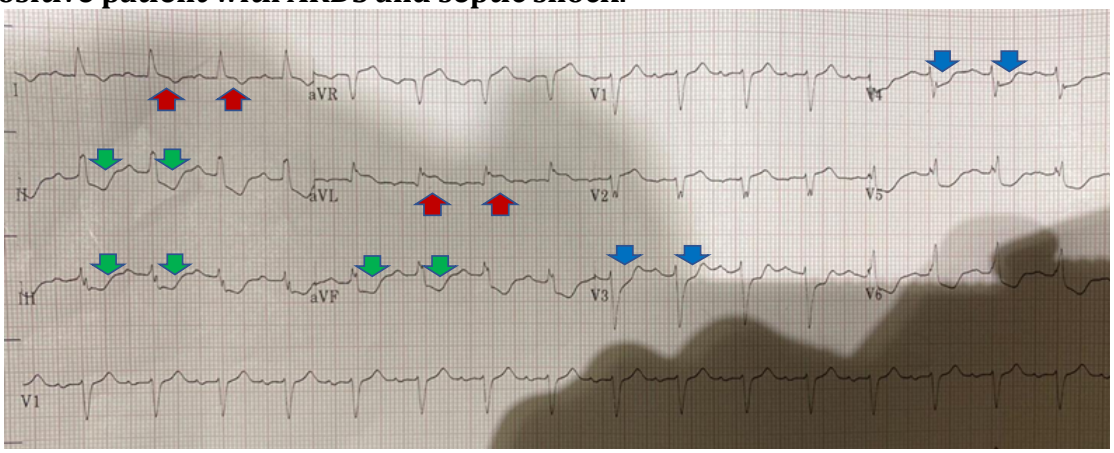

Teaching Points:

- Patients with cardiovascular disease who develop COVID-19 have a higher risk of mortality.
- During the COVID-19 pandemic, **primary PCI remains the standard of care for definite STEMI patients at PCI capable hospitals** when it can be provided in a timely fashion, with an expert team outfitted with PPE in a dedicated CCL room.
- A fibrinolysis-based strategy may be entertained at non-PCI capable referral hospitals or in specific situations where primary PCI cannot be executed or is not deemed the best option.
- Avoid reperfusion therapy for those with other causes of ST-segment elevation on the electrocardiogram (ECG).
- **There is a recognition of two major challenges in providing recommendations for AMI care in the COVID-19 era [1]:**
    - Cardiovascular manifestations in the COVID-19 patient are complex: patients may present with AMI, myocarditis simulating a STEMI presentation, stress cardiomyopathy, non-ischemic cardiomyopathy, coronary spasm, or myocardial injury without a documented Type I or Type II AMI.
    - The prevalence of COVID-19 disease in the US population remains unknown. In certain regions, community spread of SARS-CoV2 is prevalent, and the sensitivity of testing is imperfect. Further, patients testing positive for COVID-19 can be asymptomatic despite significant abnormalities noted on chest-computed tomography (CT) scan and there appears to be significant risk of asymptomatic transmission of the disease.
- **Balance care approach:** Consists in how to identifying appropriate patients for invasive interventions to AMI regardless of their COVID-19 status, and maintaining the safety of healthcare workers who might be exposed to the disease as well as minimizing contamination of cardiac catheterization laboratory (CCL) facilities.
- Additional time to establish an AMI diagnosis may be indicated (e.g. in some cases, echocardiography to assess for wall motion), and/or for COVID-19 status assessment and potential treatment (e.g. respiratory support). [Refer to figure-3]
- *Thus, during the COVID-19 pandemic, there may be longer door-to balloon (D2B) times.*
- For patients who have an unclear, or equivocal, diagnosis of STEMI due to atypical symptoms, diffuse ST-segment elevation or atypical ECG findings, or a delayed presentation, additional noninvasive evaluation in the ED is recommended.
- **Not all COVID-19 patients with ST elevation with/without an acute coronary occlusion will benefit from any reperfusion strategy or advanced mechanical support.**
- In COVID19 confirmed patients with severe pulmonary decompensation (adult respiratory distress syndrome) or pneumonia who are intubated in the ICU and felt to have an excessively high mortality (futile prognosis), consideration for compassionate medical care may be appropriate (as seen with current case in discussion).
- Recent retrospective study evaluating clinical and angiographic outcomes in patients with **STEMI with +COVID-19**, demonstrated that ***40% had no culprit lesion and with type-2 AMI*** [2] (figure-4).

Figure 3. Suggested Care for ST Elevation on Electrocardiogram at Primary Percutaneous Coronary Intervention (PCI) Center [1].

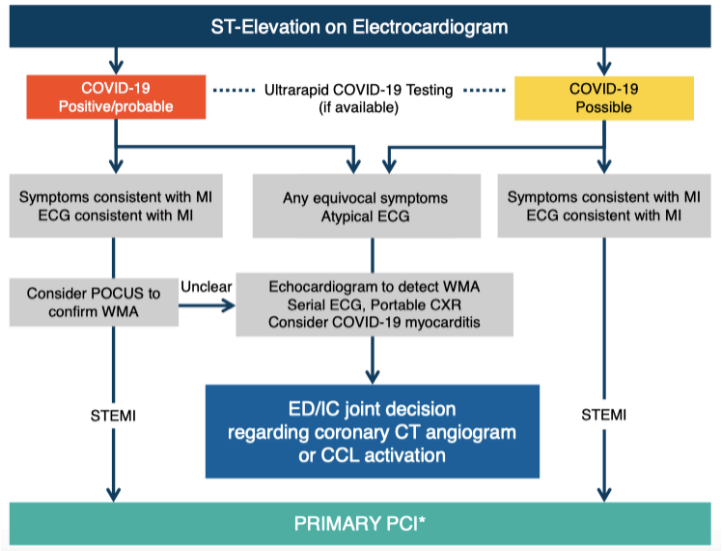

Figure 4. ST-Elevation Myocardial Infarction in Patients with COVID-19: Clinical and Angiographic Outcomes. [Ref-2]

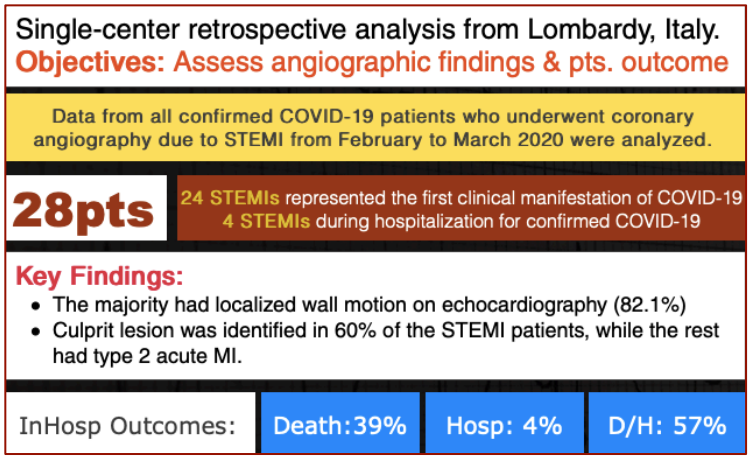

References:

1. Mahmud E, Dauerman H, Welt F, et.al. Management of Acute Myocardial Infarction During the COVID-19 Pandemic. JACC 2020; April 21: [Epub ahead of print].
2. Stefanini GG, Montorfano M, Trabattoni D, et al. ST-Elevation Myocardial Infarction in Patients with COVID-19: Clinical and Angiographic Outcomes. Circulation 2020; April 30: [Epub ahead of print].