



SHARK FIN OCCLUSIVE MYOCARDIAL INFARCTION ECG PATTERN POST-CARDIAC ARREST MISINTERPRETED AS VENTRICULAR TACHYCARDIA

Richard D. Silva-Cantillo¹, Porfirio E. Díaz-Rodríguez², Jose Escabí-Mendoza¹

¹Cardiology Section, Medical Service, Department of Veterans Affairs Caribbean Healthcare System, San Juan, Puerto Rico.

²Internal Medicine Service, Department of Veterans Affairs Caribbean Healthcare System, San Juan, Puerto Rico.



INTRODUCTION

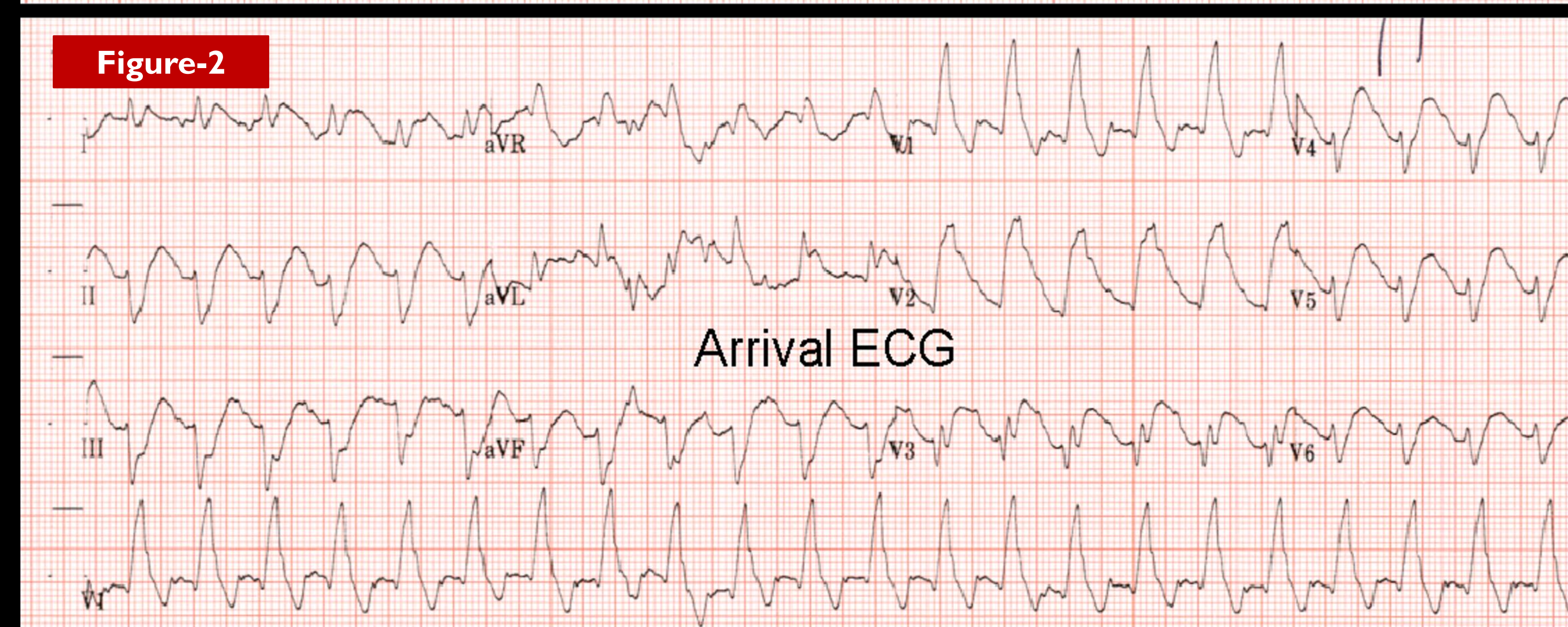
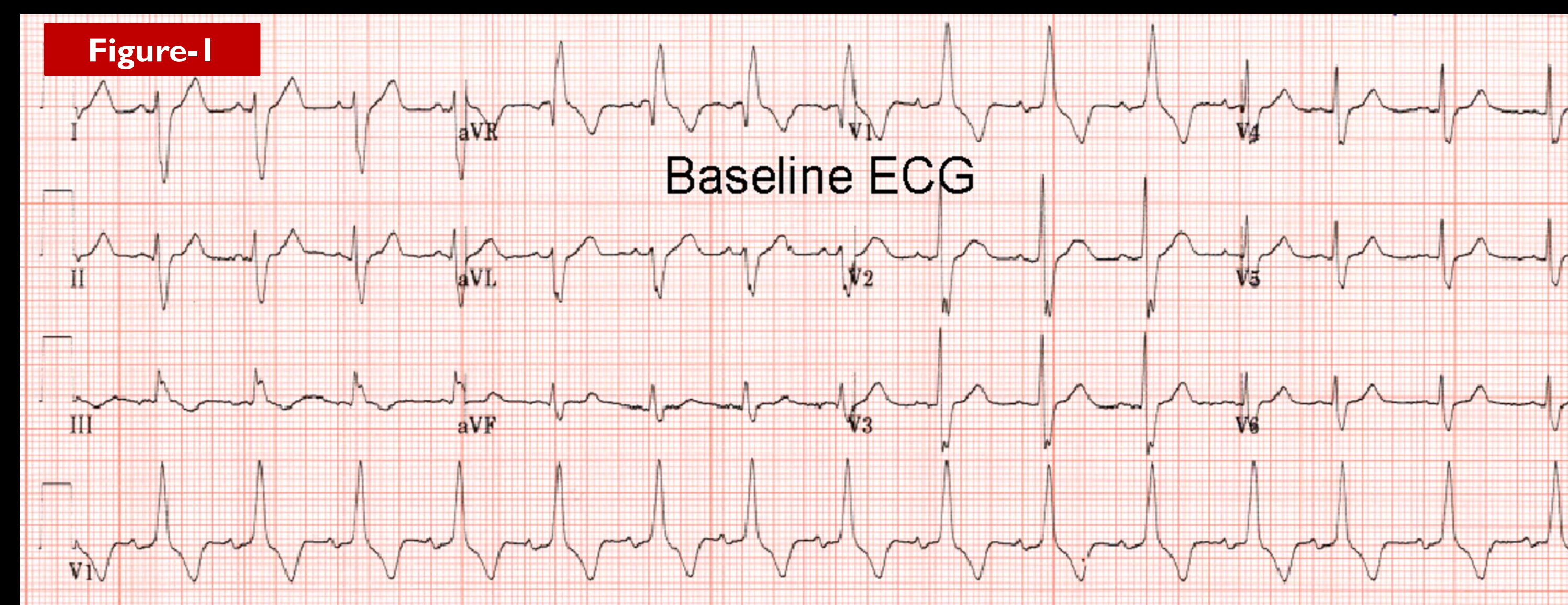
In addition to the well-known convex ST-segment elevation pattern, patients with ST-segment elevation myocardial infarctions (STEMI) may present with uncommon electrocardiogram (ECG) tracings such as the “Shark-fin” pattern, formed by the fusion of the QRS, ST-segment, and T-wave resulting in a singular wide triangular morphology, which can be potentially misinterpreted.

CASE PRESENTATION

A 79-year-old man with history of interstitial lung disease, non-obstructive coronary artery disease, psoriasis, and obstructive sleep apnea, was brought to the emergency department (ED) by paramedics with 2-hour history of ongoing chest pain. On the way to the hospital, the patient developed cardiac arrest associated to ventricular fibrillation, that required electric cardioversion and active CPR prior to arrival to the ED. Upon ED arrival the patient was unresponsive, with a heart rate of 150/min and with ECG (figure-2) evidence of a wide-QRS tachycardia, that was misinterpreted as ventricular tachycardia (VT). He was further managed with intravenous amiodarone treatment, mechanical ventilation, sedation and unsuccessful repeat electric shock therapy.

Upon persistence of the wide-QRS tachycardia and the development of pulmonary edema, the on-call cardiology team was called for emergent assistance. ECG (figure-3) was thoroughly reviewed and found with sinus tachycardia with a right bundle branch block QRS morphology, LAFB, and an extensive anterolateral STEMI with anterior and lateral precordial ST-segment elevations on leads V1 to V6, I and aVL, and reciprocal ST-segment depression on leads II, III and aVF. A bedside echocardiogram revealed severe left ventricular systolic dysfunction and marked anterolateral and apical akinesia. He was rushed to the Cath-Lab where emergent coronary angiography found an ostial left anterior descending (LAD) 100% occlusion. He underwent a successful PCI stenting under hemodynamic support with Impella CP assist device, requiring persistent inotropic and mechanical hemodynamic assistance after the procedure. Despite the above interventions the patient died from advanced multiorgan failure and refractory VT storm.

ECG AND ANGIOGRAPHY



SHARK FIN PATTERN STEMI EQUIVALENT

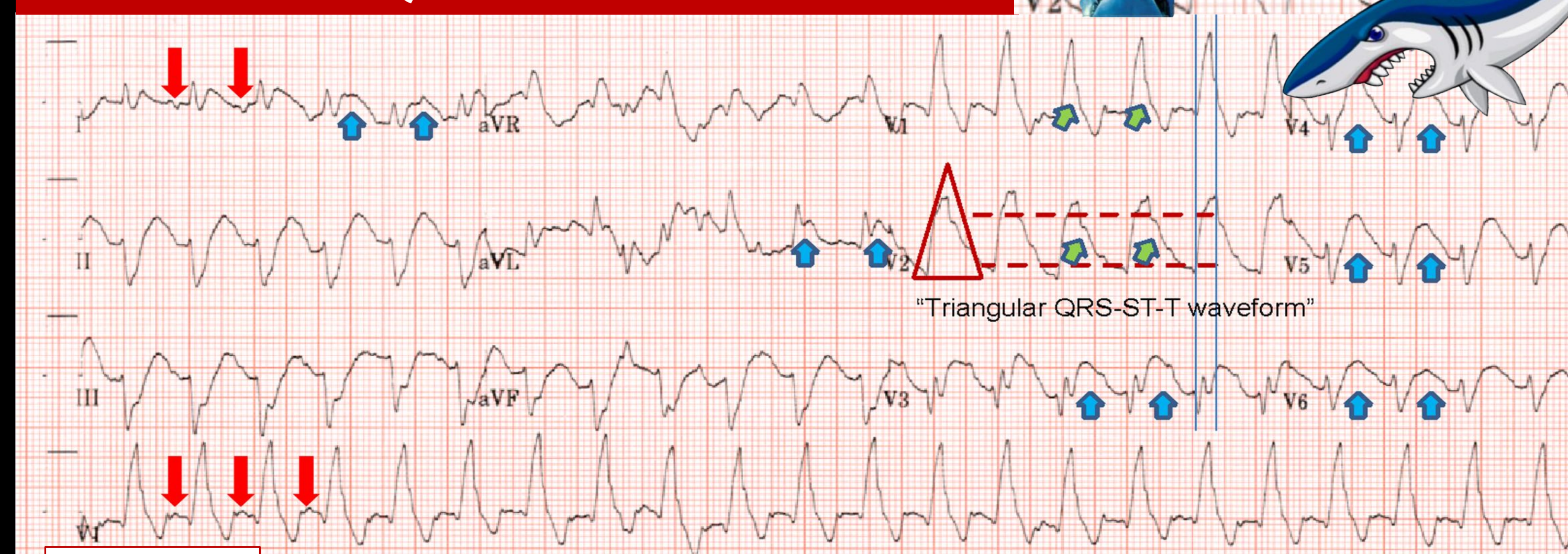
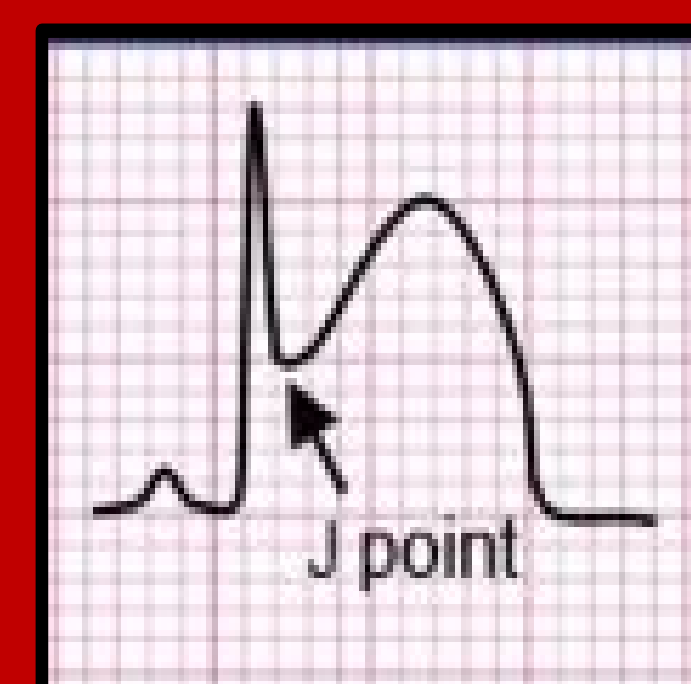
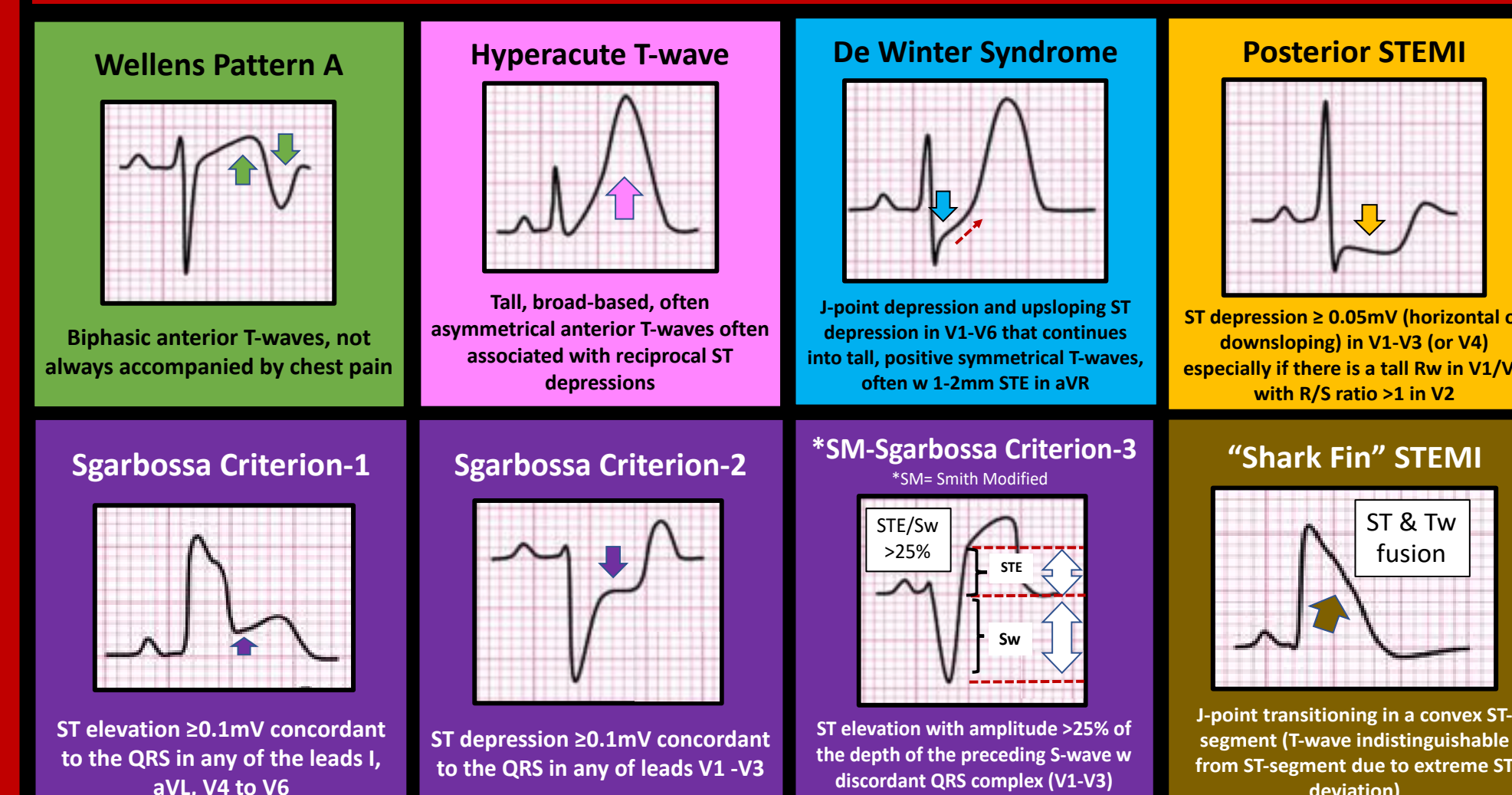


Figure-4 Conventional STEMI

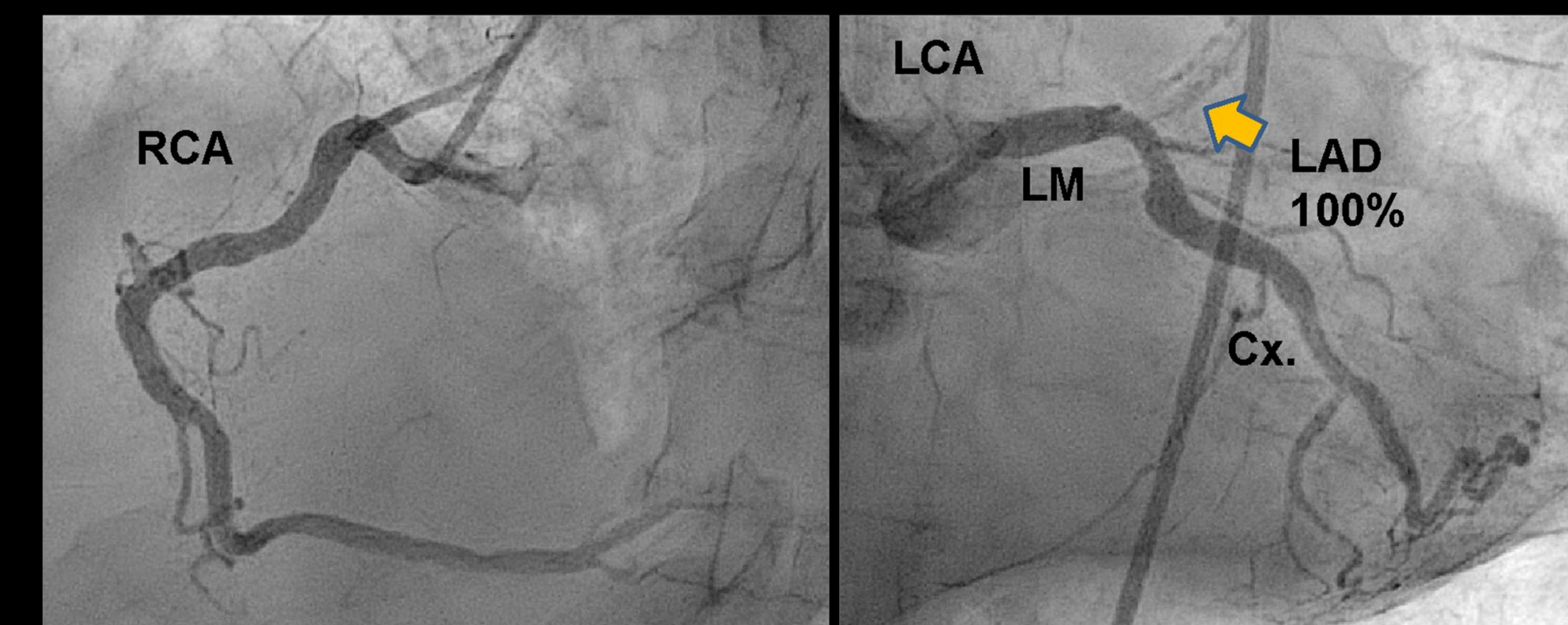


Elevation of ST segment at (or 40ms after) the J point ≥ 2 mm in V2-3, or ≥ 1 mm in any other leads and w contiguous leads.

OTHER OCCLUSIVE MYOCARDIAL INFARCTION (OMI) STEMI EQUIVALENT PATTERNS



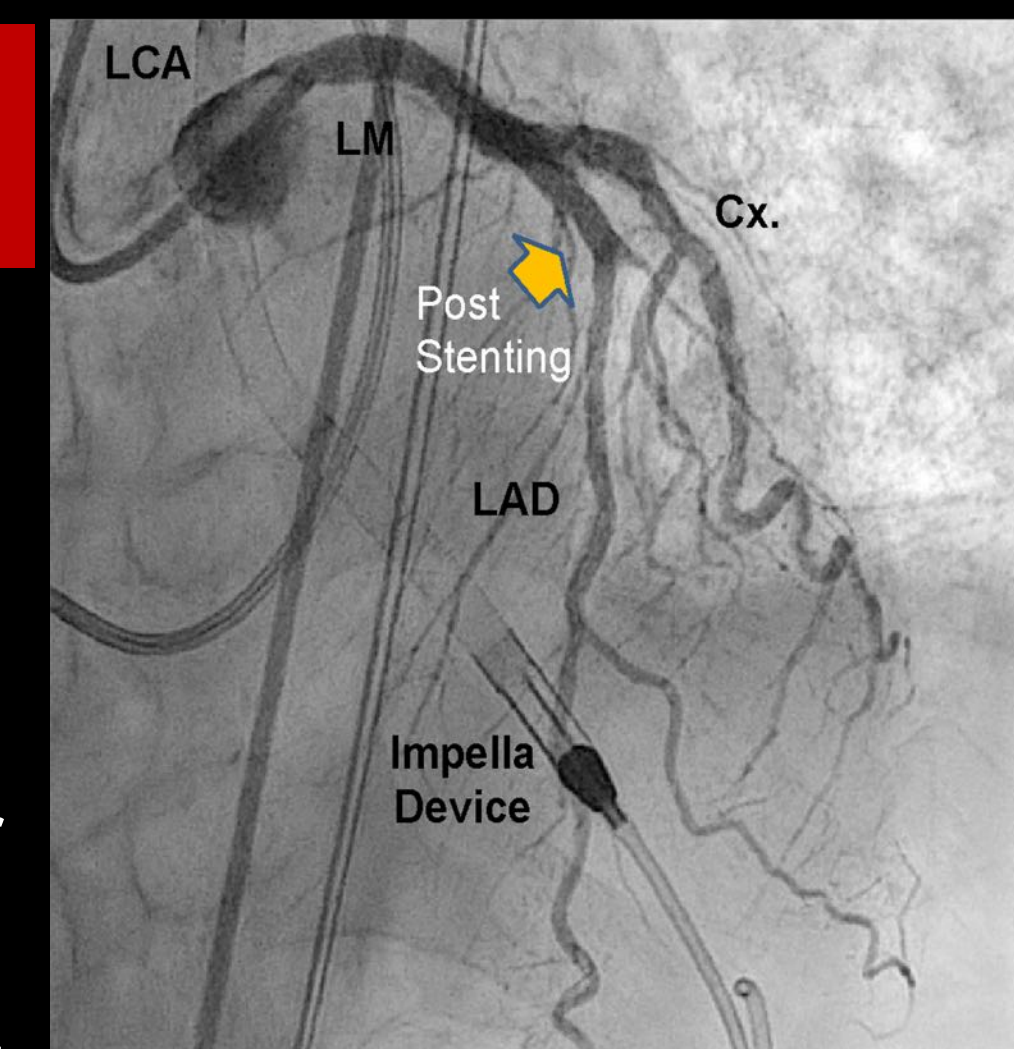
ANGIOGRAPHY



DISCUSSION

This case illustrates an uncommon ECG pattern of OMI, found on less than 1.5% of patients, yet associated with a high risk of mortality from cardiogenic shock or ventricular fibrillation (1). The Shark-fin pattern may arise irrespective of the culprit artery.

provided that a large amount of ischemic myocardium is present; however, the left main or the LAD are the most common culprits. We believe that this pattern must be added to the increasing list of OMI that do not meet the rigid STEMI definition, such as Wellen's syndrome, peak T-waves with hyperacute OMI, De Winter's T-wave, Sgarbossa criteria for OMI in LBBB or RV pacing, Aslanger's pattern and isolated anterior precordial ST depressions with posterior OMI (figure-4). This ECG pattern may be misdiagnosed as a wide complex tachycardia, as occurred in this case, leading to delay of STEMI diagnosis. Early recognition of high-risk STEMI or OMI patterns is critical to avoid delays in reperfusion therapy and to prepare for prompt use of ventricular hemodynamic support if needed.



REFERENCES

- Cipriani A, D'Amico G, Brunello G, Perazzolo Marra M, Migliore F, Cacciavillani L, et al. The electrocardiographic “triangular QRS-ST-T waveform” pattern in patients with ST-segment elevation myocardial infarction: incidence, pathophysiology and clinical implications. J Electrocardiol. 2018;51(1):8–14.
- Smith, S. W., Meyers, P., & Weingart, S. (n.d.). The OMI Manifesto Dr. Smith's ECG Blog and EMCrit , MD, FCCM Stephen Smith, MD.